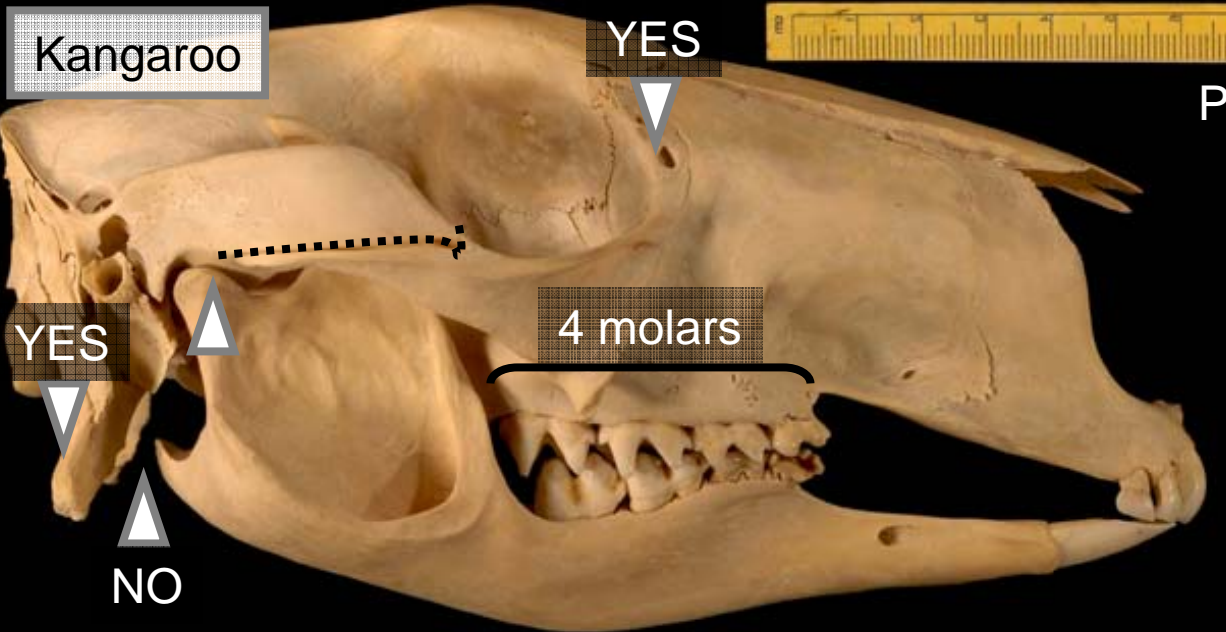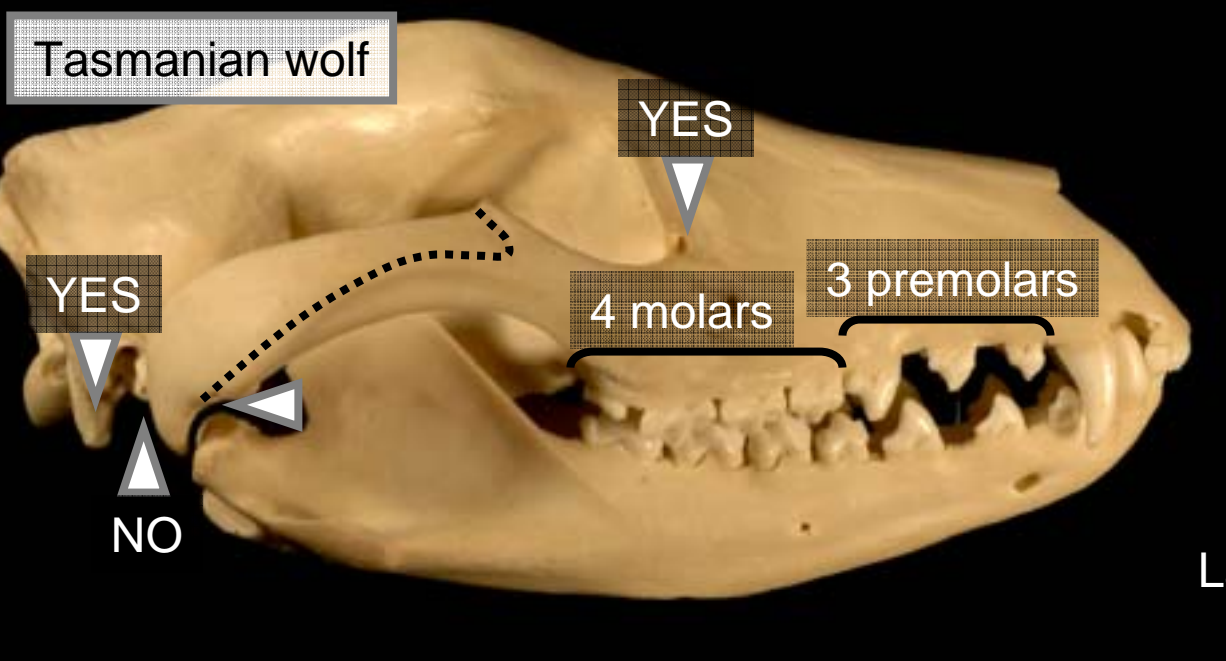


Para-occipital process present

Ear bulla present

Cheek bone & jaw joint



Tooth formula

Lacrimal bone visible from side